

See discussions, stats, and author profiles for this publication at: <https://www.researchgate.net/publication/355094735>

High prevalence of Picornavirus and Mycoplasma in free-living Hermann's tortoises *Testudo hermanni* in L'Albera Mountains, Catalonia (NE Spain)

Article · October 2021

CITATIONS

0

READS

199

5 authors, including:



Albert Martinez Silvestre

CRARC (Catalonian Reptiles and Amphibians Rescue Center)

485 PUBLICATIONS 1,179 CITATIONS

[SEE PROFILE](#)



Beate Pfau

Deutsche Gesellschaft für Herpetologie und Terrarienkunde - German Society for ...

49 PUBLICATIONS 53 CITATIONS

[SEE PROFILE](#)

Some of the authors of this publication are also working on these related projects:



INTERREG ECTOPYR 2016-2019: Pyrenean Herps as indicators of climatic change. [View project](#)



ECTOPYR [View project](#)

High prevalence of *Picornavirus* and *Mycoplasma* in free-living Hermann's tortoises *Testudo hermanni* in L'Albera Mountains, Catalonia (NE Spain)

Albert Martínez-Silvestre^{1*}, Joan Budó², Andreu Cufí², Joaquim Soler¹ and Beate Pfau³

¹CRARC, Catalanian Reptiles and Amphibians Rescue Centre 08783, Masquefa, Barcelona, Spain

²CRT Albera, Garriguella, Girona, Spain

³DGHT, German Herpetological Society, Salzhemmendorf, Germany

*Corresponding author: A. Martinez-Sylvestre, email: crarc@amasquefa.com

Introduction

The Western Mediterranean tortoise (*Testudo hermanni hermanni*) (Fig. 1) population in Catalonia is subject to a conservation programme that aims to safeguard the species in the only remaining site of natural occurrence, the Serra de l'Albera in the North of Catalonia, and to reintroduce these tortoises into various areas of its former range (Bertolero et al. 2011). Currently there are introduced populations in the Garraf Massif, in the Montsant mountain range, Llaberia Massif, and in the Ebro Delta. In addition, there are several programmes of captive breeding of tortoises in many different institutions for reintroduction into the wild (Martínez-Silvestre & Soler 2019a). These breeding projects make the most of the reproductive potential of the female tortoises; they use natural or artificial incubation of the eggs, and the hatchlings are head-started to an age of about four years before they are released into suitable habitats. However, from the beginning these programmes had two main problems: one is the very slow recovery of the free-living populations in the Albera region (Vila de Vicente et al. 2017), and the other is the high mortality of the juveniles at the age of two or three years (Martínez-Silvestre et al. 2012).

Well-known negative influences on the conservation of *Testudo hermanni hermanni* in the Albera region are, among others, the deterioration and fragmentation of suitable habitat, the frequent forest fires in this region, and the illegal private collection and keeping of these tortoises; but until recently, the role of emerging turtle diseases has been largely unknown. That is why we carried out health surveys from 2018 until 2020 on the tortoises in the breeding programmes as well as on the truly native (not introduced)



Fig. 1. A healthy western Hermann's tortoise (*Testudo hermanni hermanni*) in its natural habitat: Albera massif. Photo by CRT Albera.

tortoises in the Serra de l'Albera. This population consists mainly of animals that have never lived in captivity, but in some areas of the Albera mountains, the population has been reinforced by captive-bred tortoises which had been hatched for this purpose in the breeding centre (Centre de Reproducció de Tortugues de l'Albera: CRT).

Case studies and methodology

In Catalonia, and especially in the Albera region, clinical analyses have taken place in the free-living tortoise population, far away from the population reinforcement sites. We used Polymerase Chain Reaction (PCR) to detect whether the tortoises had *Ranavirus*, *Mycoplasma*, *Herpesvirus*, or *Picornavirus* infections. The first confirmed case of *Picornavirus* infection in Catalonia occurred in 2019 in a *Testudo hermanni* breeding centre, where we found out, by using PCR and histology, that the principal reason for the high juvenile mortality was in fact this virus (Martínez-Silvestre et al. 2020; Pfau et al. 2020). This breeding centre is situated in the south of Catalonia and fairly far away from the Albera region, but it is within the natural range of the Mediterranean tortoise in Catalonia, and therefore it was considered important to also analyse the other known populations in this species' area of distribution. *Picornavirus* is a pathogen which was recently confirmed as

a cause of mortality outbreaks in juvenile tortoises world-wide (Paries et al. 2019). Against this background we decided in 2020 to broaden the adult tortoise health survey in the free-living population in the Serra de l'Albera, and also to include serological analyses for *Picornavirus* and *Herpesvirus* in the health survey.

The animals were caught in the wild and released back immediately after the samples had been taken. The sampling was performed by the first author of this paper. All the tortoises were marked by shell notching and included in the catalogue of the population density survey (Bertolero et al. 2020). The population density of the tortoises in the Albera region is very low, and it was quite difficult to find a large number of tortoises, but we consider the number of sampled tortoises in the three years of the survey (41 individuals from different habitats) as a good indicator of the health status of the whole population.

For the PCR, an oropharyngeal swab was taken (Fig. 2), and for the serological analysis we used a blood sample taken from the occipital sinus (Fig. 3), which was centrifuged and deplasmatised *in situ* by using a portable centrifuge. The swabs and the plasma samples were submitted to the Laboklin laboratory, 97688 Bad Kissingen, Germany (Marschang 2020) for analysis.

Table 1: Number of tortoises tested.

	PCR (<i>Ranavirus</i>, <i>Mycoplasma</i>, <i>Herpesvirus</i>, <i>Picornavirus</i>)	Serology <i>Herpesvirus</i>	Serology <i>Picornavirus</i>
2017	9	0	0
2018	17	17	0
2020	15	15	15



Fig. 2. Taking an oral swab in an adult wild (free-living) tortoise.
Photo by Albert Martínez-Silvestre.

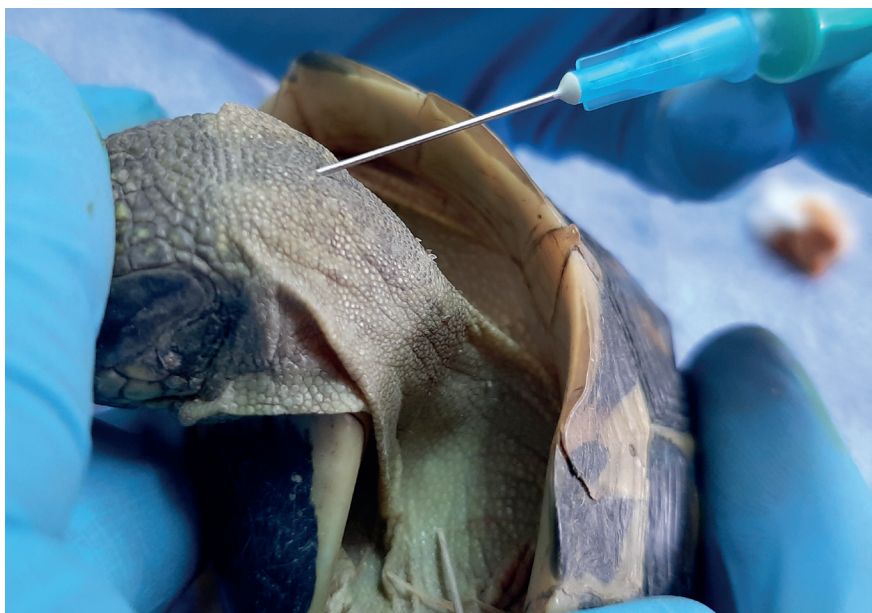

Fig. 3. Taking a blood sample from the occipital sinus of an adult free-living tortoise.
Photo by Albert Martínez-Silvestre.

Table 2: Analysis results of adult tortoises from the Albera tortoise population.
R= *Ranavirus*; M = *Mycoplasma*; H = *Herpesvirus*; P = *Picornavirus*.

Infection identified	Negative	R	M	H	M + H	P PCR	P serology	P + M
Free-living tortoises N=41	13	0	20	4	3	0	10	6
Total %	31.7%	0	48.7%	9.7%	7.3%	0 %	24.4%	14.6%

Discussion

Ranavirus in wild tortoises: all the tests proved negative, and we therefore think that, at present, this is not an infectious agent of significance as far as the tortoises in the Albera region are concerned.

Herpesvirus in wild tortoises: in the three years of tortoise health checks we found positive carriers (by PCR test) only in the first year, and in the subsequent years every sample was negative. The prevalence is low (9.7% of all sampled tortoises were positive). Symptomatic tortoises were seen only in captive tortoises from southern Catalonia (Fig. 4), not in free-living animals. Moreover, all the additional serological tests for this agent, carried out in 2018 and 2020, were also negative.

Mycoplasma in wild tortoises: when sampling free-living tortoises, we found very high prevalences of *Mycoplasma*: 80% in 2017, 61% in 2018 and 45% in 2020. The average prevalence (48.7%) is one of the highest values described for free-living tortoises in Europe (Allain & Duffus 2019). It is noteworthy, however, that none of the sampled tortoises showed any signs of disease which were attributable to this agent. *Mycoplasma* can pose serious conservation problems in populations of *Gopherus* spp. (Weitzman et al. 2017; Goessling et al. 2020), but from the data available so far it does not appear to pose a serious threat to populations of *Testudo hermanni*. In the French population of *T. hermanni*, 584 tortoises have been sampled, and 8.7% of them tested positive for *Mycoplasma*, but also without any obvious clinical signs of disease (Ballouard et al. 2021, in review).

Picornavirus in wild tortoises: the positive results of tests for *Picornavirus* in the free-living tortoise population were a surprise. The tortoises which had been sampled by PCR in all three years of the survey had always tested negative, but in the last year we also carried out a serological control test, and we found that 67% of tortoises tested positive. This could mean that

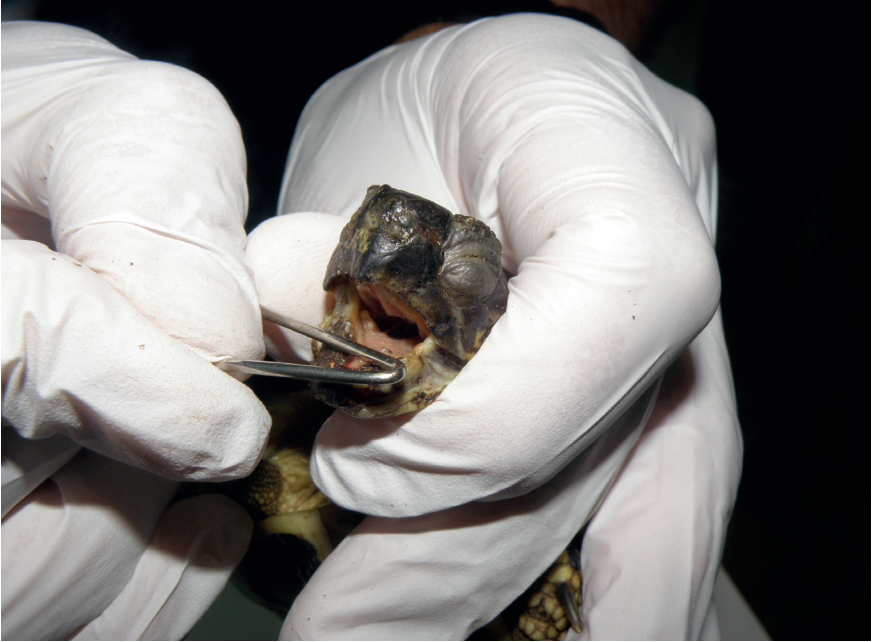

Fig. 4. A captive *Testudo hermanni* with nasal and oral infection lesions due to *Herpesvirus*. Photo by Albert Martínez-Silvestre.

the adult tortoises have had the disease, but they survived and are now asymptomatic carriers. However, juveniles of less than three years of age show an elevated mortality when they are infected with *Picornavirus*, as has been shown in a breeding centre in Catalonia (Martínez-Silvestre et al. 2019a, 2020). While no clinical signs of *Picornavirus* are observed in the adults, in the offspring of the semi-free-ranging breeding programme the clinical signs were subacute. Sick animals showed a softening of the shell, which was friable and deformable to the touch (Figs 5 & 6); they stopped growing and were sluggish. In the days before death the tortoises stopped eating, closed their eyes and no longer moved their legs, and the whole animal seemed to bulge. If cystocentesis (puncturing of the urinary bladder) was performed, an excess retention of urine could be observed. *Post-mortem* examinations revealed renal disease as well as an alteration of the carapacial bone structure, which is consistent with the findings after artificial experimental inoculation of *Picornavirus* in *Testudo hermanni* and *T. graeca* (Paries et al. 2019). As a result, we fear that this virus may actually be affecting the conservation of *Testudo hermanni* more seriously than the other pathogens for which we tested. Recently, it has been detected that this virus forms a distinct subgroup within the Picornaviridae, and has been classified as a new genus: *Torchivirus* (Marschang 2019).

Co-infections: in the health survey of the wild tortoises in the Albera region some noteworthy co-infections with different pathogens were detected: *Herpesvirus* + *Mycoplasma* in 7.3% of the sampled free-living tortoises, and *Picornavirus* + *Mycoplasma* in 14.6% of the tortoises. Again, *Picornavirus* is more prevalent than *Herpesvirus* in the co-infections. Both these co-infections could be of concern for the conservation of this tortoise species in affected animals, but given that the demonstrated pathogenicity for *Picornavirus* is higher than for *Herpesvirus* in this tortoise population, it appears that co-infection with *Mycoplasma* + *Picornavirus* may be the greater threat. This will require further studies comparing the effect of these two pathogens in controlled studies of affected individuals, especially in juvenile tortoises.

Conclusions

This health survey of the free-living population of *Testudo hermanni hermanni* in the Albera region showed an almost complete absence of *Herpesvirus*, a very high incidence of *Mycoplasma*, but without any apparent effect on health, and a worrying effect of *Picornavirus* on the health and survival of the juveniles. Since there is no effective treatment for these pathogens, the key to control is to avoid as much as possible the entry of untested breeder animals into the conservation programmes. Environmental persistence studies for *Torchivirus* show that they withstand long periods of time in cold water. Viral inactivation in the soil at summer temperatures can take more than three weeks (Marschang 2019). Prevention is, therefore, based on carrier control (testing for asymptomatic juveniles and adults), avoiding overpopulation, and adopting biosecurity measures in breeding facilities both in field work and prior to the release of any tortoises into the habitats (Martínez-Silvestre et al. 2014; Martínez-Silvestre & Soler 2019b).

Acknowledgements

We are grateful to our funding agency, the British Chelonia Group, for support of funds to carry out this study. We also thank Roser Velarde (Veterinary School, Autonomous University of Barcelona), and the Laboratorios Echevarne, Laboratorio de Técnicas Citohistológicas and the Laboratorio Laboklin for the procedures with the described laboratory techniques. We are extremely thankful to Vanessa Cadenas for her help during the field and lab works.

The CRT team applies to the Regional Government of Catalonia (Generalitat de Catalunya) for permits to handle and sample the free-living tortoises in spring each year. Permits for the capture and release procedure were obtained from the regional Government (Departament de Territori i Sostenibilitat, Govern de Catalunya, Scientific authorization SF/0582).



Fig. 5. (A) An obviously soft and deformable carapace and plastron of a hatchling *Testudo hermanni* affected by tortoise *Picornavirus* and (B) a healthy, alert and round hatchling of the same species. Photos by Albert Martínez-Silvestre.

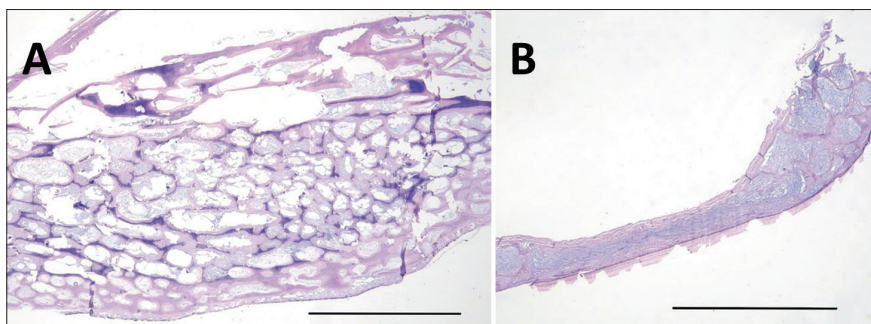


Fig. 6. Comparative histological pictures of (A) a healthy wide and porous shell bone and (B) an unhealthy, thin and compressed shell bone in *Testudo hermanni* affected by *Picornavirus*. Images courtesy of Roser Velarde.

References

- Allain, S.J.R. & Duffus, A.L.J. (2019). Emerging infectious disease threats to European herpetofauna. *Herpetological Journal* 29: 189-206.
- Ballouard, J.M., Bonnet, X., Jourdan, J., Martinez-Silvestre, A., Gagno, S., Fertard, B. & Caron, S. (2021). First detection of *Herpesvirus* and *Mycoplasma* in wild Hermann's tortoises (*Testudo hermanni*), and in potential pet vectors. *BioRxiv*. <https://doi.org/10.1101/2021.01.22.427726> (preprint).
- Bertolero, A., Cheylan, M., Hailey, A., Livoreil, B. & Willemsen, R.E. (2011). *Testudo hermanni* (Gmelin 1789) – Hermann's Tortoise. In: Rhodin, A.G.J., Pritchard, P.C.H., van Dijk, P.P., Saumure, R.A., Buhlmann, K.A., Iverson, J.B. & Mittermeier, R.A. (eds). *Conservation Biology of Freshwater Turtles and Tortoises: A Compilation Project of the IUCN/SSC Tortoise and Freshwater Turtle Specialist Group*. *Chelonian Research Monographs* No. 5, pp. 059.1-059.20.
- Bertolero, A., Budó, J. & Torres, N. (2020). Característiques poblacionals de la tortuga mediterrània *Testudo hermanni hermanni* Gmelin, a la serra de l'Albera (Reptilia: Testudinae). *Butlletí de la Institució Catalana d'Història Natural* 84: 131-136.
- Goessling, J.M., Guyer, C., Godwin, J.C., Hermann, S.M., Sandmeier, F.C., Smith, L.L. & Mendonça, M.T. (2020). Upper respiratory tract disease and associated diagnostic tests of mycoplasmosis in Alabama populations of Gopher tortoises, *Gopherus polyphemus*. *PLoS ONE* 14(4): e0214845.
- Kolesnik, E., Obiegala, R. & Marschang, R.E. (2017). Detection of *Mycoplasma* spp., herpesviruses, topiviruses, and ferlaviruses in samples from chelonians in Europe. *Journal of Veterinary Diagnostic Investigation* 29: 820-832.
- Marschang, R.E. (2019). Virology. In: Divers, S.J. & Stahl, S.J. (eds). *Mader's Reptile and Amphibian Medicine and Surgery*. Third Edition, Elsevier / Saunders, London, pp. 247-269.
- Marschang, R.E. (2020). Viruserkrankungen der Reptilien in der tierärztlichen Praxis [Viral diseases of reptiles in clinical practice]. *Tierärztliche Praxis Ausgabe K: Kleintiere und Heimtiere* 48(2): 119-131.
- Martínez-Silvestre, A., Cadenas, V., Soler, J., Martínez, D., Pena, L. & Velarde, R. (2020). Infección por *Picornavirus* en tortuga mediterránea (*Testudo hermanni*) en un programa de conservación in situ en Cataluña. *Boletín de la Asociación Herpetológica Española* 31(1): 5-9.
- Martínez-Silvestre, A., Martínez, C., Soler, J., Sanuy, D., Budó, J. & Capalleras, X. (2012). Causes of death in conservation programs of Herman's tortoise (*Testudo hermanni*) in Catalonia (Spain). *Congreso Luso Español de Herpetología* XII: 84-85.
- Martínez-Silvestre, A., Soler, J., Budó, J., Vilardell-Bartino, A. & Capalleras, X. (2014). Health prophylaxis in reintroduction projects of the Hermann's tortoise in Spain. In: Caron, S. (ed.). *Proceedings of the international workshop on the management and restoration of Hermann's tortoise populations and habitats*, Le-Luc-en-Provence. *Chelonii* 9: 76-78.

- Martínez-Silvestre, A. & Soler, J. (2019a). Management of Mediterranean Testudinids in Spanish recovery centers. *Mediterranean Workshop to Develop Tortoise Conservation Strategies* 1: 29.
- Martínez-Silvestre, A. & Soler, J. (2019b). Diseases of interest and biosecurity in the conservation of Spanish *Testudo*. *Mediterranean Workshop to Develop Tortoise Conservation Strategies* 1: 33.
- Paries, S., Funcke, S., Kershaw, O., Failing, K. & Lierz, M. (2019). The role of Virus "X" (Tortoise *Picornavirus*) in kidney disease and shell weakness syndrome in European tortoise species determined by experimental infection. *PLoS ONE* 14(2): e0210790.
- Pfau, B., Budó, J. & Martínez-Silvestre, A. (2020). Autochthone und allochthone Landschildkröten in Katalonien - Update 2020. *Testudo (SIGS)* 29(3): 4-20.
- Vila de Vicente, S., Delahunt, M. & Pfau, B. (2017). New project to save the Albera tortoise. *Radiata* 26(3): 4-22.
- Weitzman, C.L., Sandmeier, F.C. & Tracy, C.R. (2017). Prevalence and diversity of the upper respiratory pathogen *Mycoplasma agassizii* in Mojave desert tortoises (*Gopherus agassizii*). *Herpetologica* 73(3): 113-120.